

A RARE CASE OF PING PONG FRACTURE IN A 1.5 YEAR OLD CHILD WITH GOOD OUTCOME**Mallappa Huggi¹**¹Assistant Professor, Department of Neurosurgery, Shri B. M Patil Medical College, Vijayapura, Karnataka, India.

Received : 09/05/2025
 Received in revised form : 01/07/2025
 Accepted : 18/07/2025

Keywords:

Colonoscopy, Dexmedetomidine, Propofol, Sedation, Ramsay Sedation Score, Analgesia, Recovery time, Respiratory depression.

Corresponding Author:

Dr. Mallappa Huggi,

Email: mallikarjunvh@gmail.com

DOI: 10.47009/jamp.2025.7.4.229

Source of Support: Nil,
 Conflict of Interest: None declared

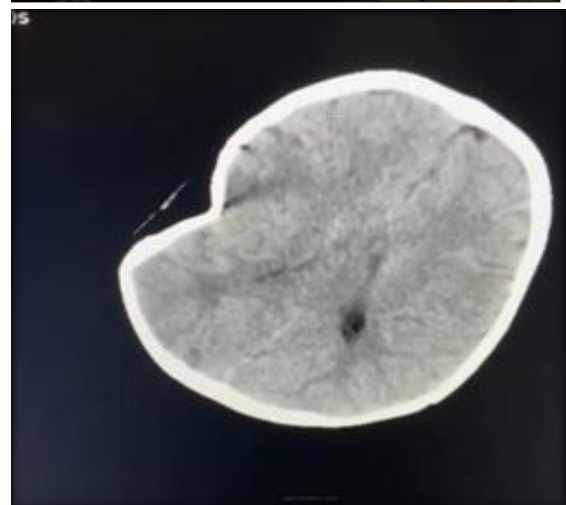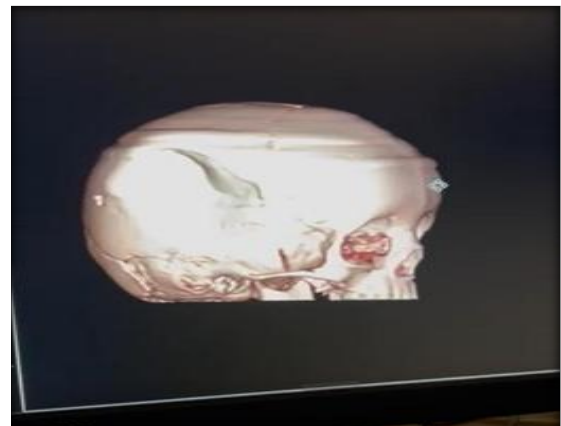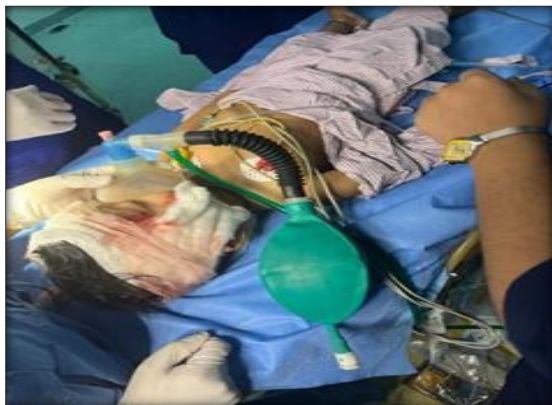
Int J Acad Med Pharm
 2025; 7 (4); 1212-1214

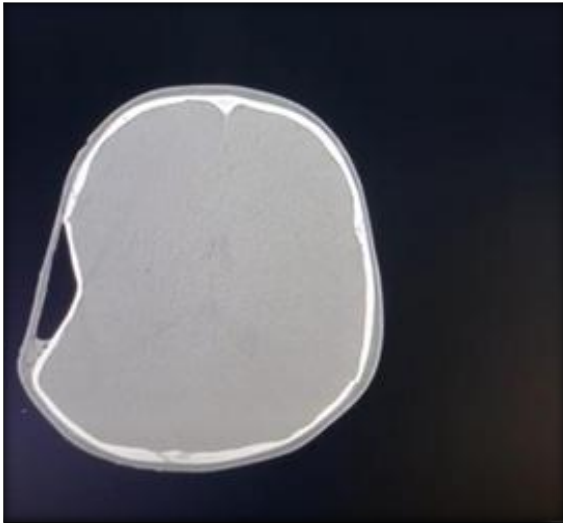
**ABSTRACT**

Ping pong fractures of skull occur exclusively in infants and toddlers as the skull bone is malleable(pliable) in this age group. These fractures can occur due to birth injury, following trivial fall while playing and RTA. The management of such injuries is a topic of discussion. Management of these cases depends predominantly on the severity of injury. Early intervention helps to prevent neurological deficit and other long term complications.

INTRODUCTION

A 1.5-year-old child was brought to emergency room following being forcefully hit by car. He was brought in a drowsy state with stable vitals, on evaluation abrasion injury over scalp and depression of skull bone was noted. Child was taken up for CT brain with 3D reconstruction which revealed a very severe ping pong fracture.





The child underwent emergency surgery

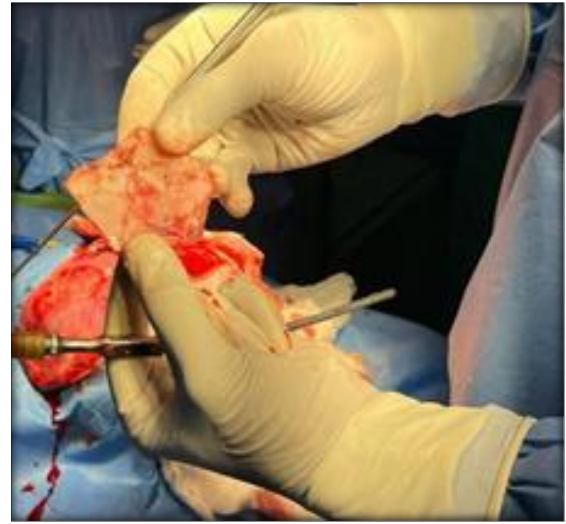

Image 7 Depression noted in the elevated skull fragment

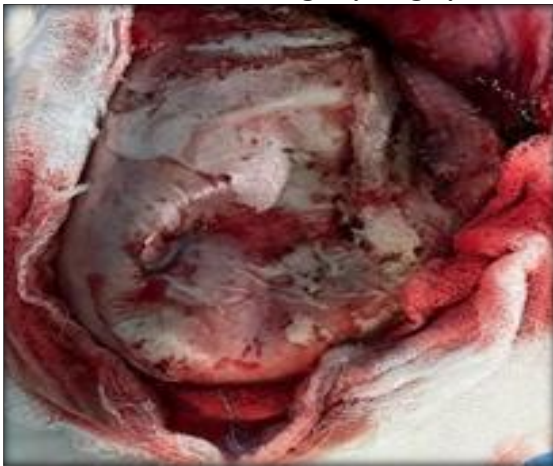

Image 5 Depressed fracture after elevation of scalp flap

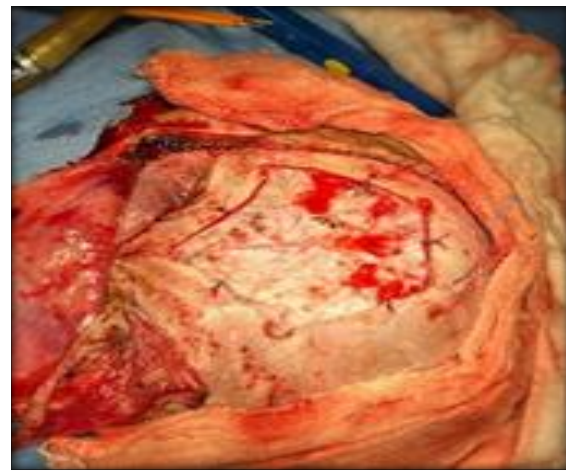

Image 8 Dural haemostasis being achieved and dural hitches are placed to prevent EDH

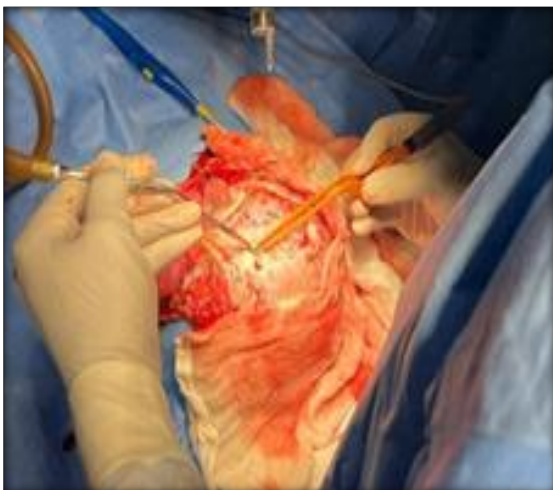


Image 6 Craniotomy done all around the depressed fragment and depressed fragment elevated

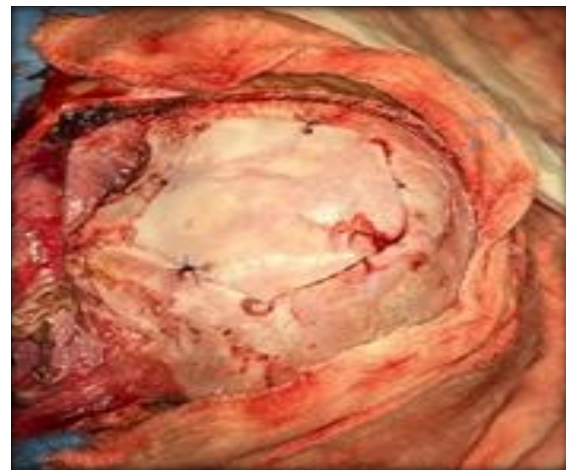


Image 9 Depressed bone fragment is moulded and replaced over calvarial defect, it is anchored using sutures.

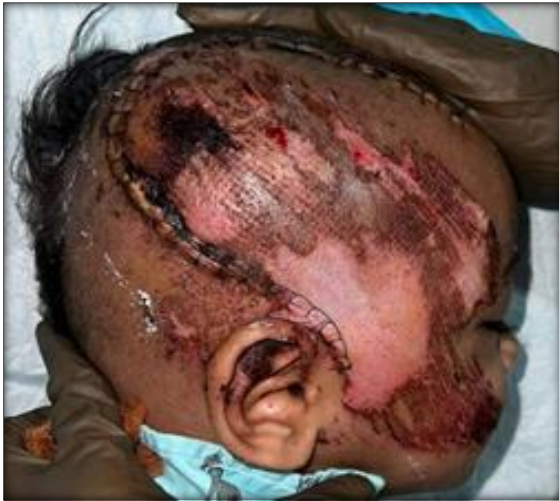

Image 10 Final outcome after Scalp closure

Outcome and follow up

The child made an excellent recovery and was discharged on POD 6. Early intervention prevented any neurological deficit even though there was severe compression on the parenchyma.

DISCUSSION

Ping pong fractures are rare, their management poses a significant challenge in view of vulnerability of this population. Minimal depressed ping pong fracture can be conservatively managed. In case of severe depressed fracture with mass effect on the parenchyma warrants surgical management to prevent any neurological deficit and for cosmetic reasons.

In our case, the child did not have any neurological deficit, but surgical correction was justified in view of severity of the depression and potential long-term cosmetic concerns. Various techniques for elevation

of depressed fractures include digital pressure application, vacuum-assisted devices application, and minimally invasive surgical approaches. In our case we planned for open elevation of depressed fracture.

CONCLUSION

This case emphasizes the importance of customized approach in decision making for ping pong fractures. Some cases may resolve spontaneously, surgical intervention is a safe and effective approach for severe depressed. Early and appropriate management can result in optimal functional and cosmetic outcomes.

Summary

Depressed skull fracture in a toddler resemble a ping pong deformity due to pliability of skull bone. These are rare and often seen due to birth injuries or blunt trauma to head. A 1.5-year-old child met with RTA (was hit by a car) following which he developed ping pong fracture of skull. He was evaluated and treated on emergent basis with good surgical outcome.

REFERENCES

1. Reddy, M. P., & Gupta, S. K. (2019). "Management of Paediatric Skull Fractures: A Review." *Journal of Paediatric Neurosurgery*, 54(3), 120-126.
2. Beatty, H. K., & Paterson, D. (2018). "Depressed Skull Fractures in Children: Conservative vs Surgical Management." *Paediatric Neurosurgery*, 49(2), 98-105.
3. Hwang, S. W., & Thomas, M. R. (2020). "Ping Pong Fractures in Neonates and Infants: Clinical and Surgical Considerations." *Journal of Neurosurgery: Paediatrics*, 25(4), 345-351.
4. Lober, R. M., & McBride, S. M. (2017). "Paediatric Head Trauma: Diagnosis and Treatment Guidelines." *The Journal of Trauma and Acute Care Surgery*, 83(6), 1125-1133.
5. Mahapatra, A. K., & Kamal, R. (2016). "Paediatric Neurosurgery: Current Trends and Future Directions." *World Journal of Paediatric Surgery*, 12(1), 1-9.